

A Modified Surgical Approach for the Treatment of Classic Ameloblastoma in Young Patients

Xiao Peng, Chenchen Zhang, Mo Chen, Kai Zhang*

Department of Stomatology, First Affiliated Hospital of Bengbu Medical College, Bengbu, Anhui, 233000, China.

How to cite this paper: Xiao Peng, Chenchen Zhang, Mo Chen, Kai Zhang. (2023) A Modified Surgical Approach for the Treatment of Classic Ameloblastoma in Young Patients. *International Journal of Clinical and Experimental Medicine Research*, 7(1), 99-102.
DOI: 10.26855/ijcemr.2023.01.017

Received: December 18, 2022

Accepted: January 15, 2023

Published: February 7, 2023

*Corresponding author: Kai Zhang, Department of Stomatology, First Affiliated Hospital of Bengbu Medical College, Bengbu, Anhui, 233000, China.

Abstract

Objective: To analyze the clinical efficacy and application characteristics of the sequence method in the treatment of young patients with large cystic classic ameloblastoma (AM). **Methods:** 16 young patients with large cystic classic AM treated in the Department of Stomatology of the First Affiliated Hospital of Bengbu Medical College from February 2012 to August 2019 were selected. According to the patient's age, imaging examination, and pathological diagnosis, the sequence method was used for treatment. The patients were followed up regularly after the operation. **Results:** The patients were followed up for more than 2 years. Of the 16 patients, 13 had no recurrence after fenestration + first curettage, 3 had recurrence after fenestration + first curettage, and 2 had no recurrence after secondary curettage. One patient recurred after repeated curettage and followed up for 10 years and underwent osteotomy. **Conclusion:** Sequence method can play a good therapeutic effect on young large cystic classic AM.

Keywords

Classic AM, Sequence method, The young, Fenestration decompression, Curettage

1. Introduction

Ameloblastoma (AM) is a typical benign odontogenic tumor, accounting for 59.3% ~ 63.2% of odontogenic tumors [1-3]. It is common in the jaw, 80% of which occurs in the mandible [4-6]. Studies have shown that [7, 8], fenestration decompression for single cystic am can achieve ideal results. For extraosseous/peripheral am, it is suggested to locally expand the resection of lesions to reduce the recurrence rate. Some scholars believe that [9-11], both single capsule and classic am are indications for fenestration decompression, but there is no conclusion as to whether a secondary operation is required after fenestration, when, and how. Given the above problems, our research group proposes to implement the sequence method for young patients with large cystic classic am. The purpose of this study is to analyze the efficacy of the sequence method on young people with large cystic classic am, to provide a useful reference for the treatment of this kind of patient.

2. Material and method

2.1 General information

According to the inclusion criteria, 16 young patients with large cystic classic am were selected from the Department of Stomatology of the First Affiliated Hospital of Bengbu Medical College from February 2012 to August 2019, including 12 males and 4 females, aged from 13 to 24 years, with an average age of 18.47 ± 6.14 years. The

pathological results showed that all 16 patients were classic am, including 12 cases of plexus type and 4 cases of follicular type.

2.2 Inlet and discharge standards.

Inclusion criteria: (1) select young people aged 13-24 according to who age classification standard in 2021; (2) It was proved to be classical am by pathology; (3) The maximum diameter of the capsule is $> 3.5\text{cm}$; (4) Newly diagnosed patients were treated with sequence method. This study has been approved by the ethics committee of Bengbu Medical College (approval No.2014010), and all patients have signed informed consent (Table 1).

Table 1. Demographic data (age, sex distribution) and lesion sites for patients undergoing the dredging method for classic ameloblastoma (n=16)

Age range	Gender		Site of lesion		Total
	Male	Female	Mandibular ramus	Mandibular body and angle	
13-16	5	1	2	3	6
17-20	4	1	3	2	5
21-24	3	2	4	1	5
Total	12	4	9	6	16

2.3 Surgical Technique

(1) Stage I fenestration decompression: The position of the fenestration is near the center of the cystic cavity and surrounded by bone wall support. The solid components in the capsule and part of the capsule wall were cut and sent to pathological examination, and the window was kept unobstructed. One week after surgery, personalized cyst plug was made, and the patient was instructed to wash the invasive cavity with 0.9% sodium chloride solution and 3% hydrogen peroxide solution every day, and the patient was re-visited every 3 months.

(2) Phase II endoscopic curettage: after the operation, when the shape of relevant important anatomical structures has been restored and will not be invaded by the focus, the tumor tissue and capsule wall in the capsule visible to the naked eye shall be removed with a curettage combined with aspirator under general anesthesia, and then the residual solid components and capsule wall shall be carefully scraped through the paranasal sinus mirror. Finally, the 1-2 mm bone around the capsule wall shall be ground with a grinding head to avoid relevant important anatomical structures. For recurrent cases during postoperative follow-up, to delay the osteotomy time, local curettage under an endoscope can be continued to preserve the continuity of the jaw and continue regular follow-up.

(3) Stage III osteotomy: for patients who relapse repeatedly after stage II operation, osteotomy will be performed after they become adults, that is, square resection of the lesion and its surrounding normal bone, and bone grafting to repair the defect at the same time; For cases with a large range of lesions, the segmental osteotomy is feasible. The patients were followed up regularly.

3. Results

3.1 Follow up results

Among the 16 patients, 13 patients were followed up for more than 2 years after stage I fenestration + stage II first endoscopic curettage, and no recurrence was found. The bone was stable after fenestration decompression and curettage. Among them, 2 patients recurred 3 months and 6 months after the first endoscopic curettage in phase II. One patient recurred after 9 years of follow-up after the first endoscopic curettage in phase II. He underwent subtotal resection of left mandible + fibula transplantation with left pedicled vascular pedicle + facial nerve anatomy + autologous bone implantation of mandible. The pathological classification of 3 patients with recurrence was a follicular type.

3.2 Typical cases

A 35-year-old female patient came to our hospital with the main complaint of "left lower posterior tooth pain for more than a week". The patient underwent fenestration decompression of the left mandibular ameloblastoma in our hospital in 2011. Follow up and take films every 3 months after the operation. Six months after phase I fenestration decompression. The first endoscopic curettage in phase II was performed, and the wound cavity was closed with

iodoform gauze. The follow-up after the operation has seen bone destruction in the original capsule. Phase III osteotomy is recommended according to the patient's age, pathological type, and bone destruction (Fig.1).

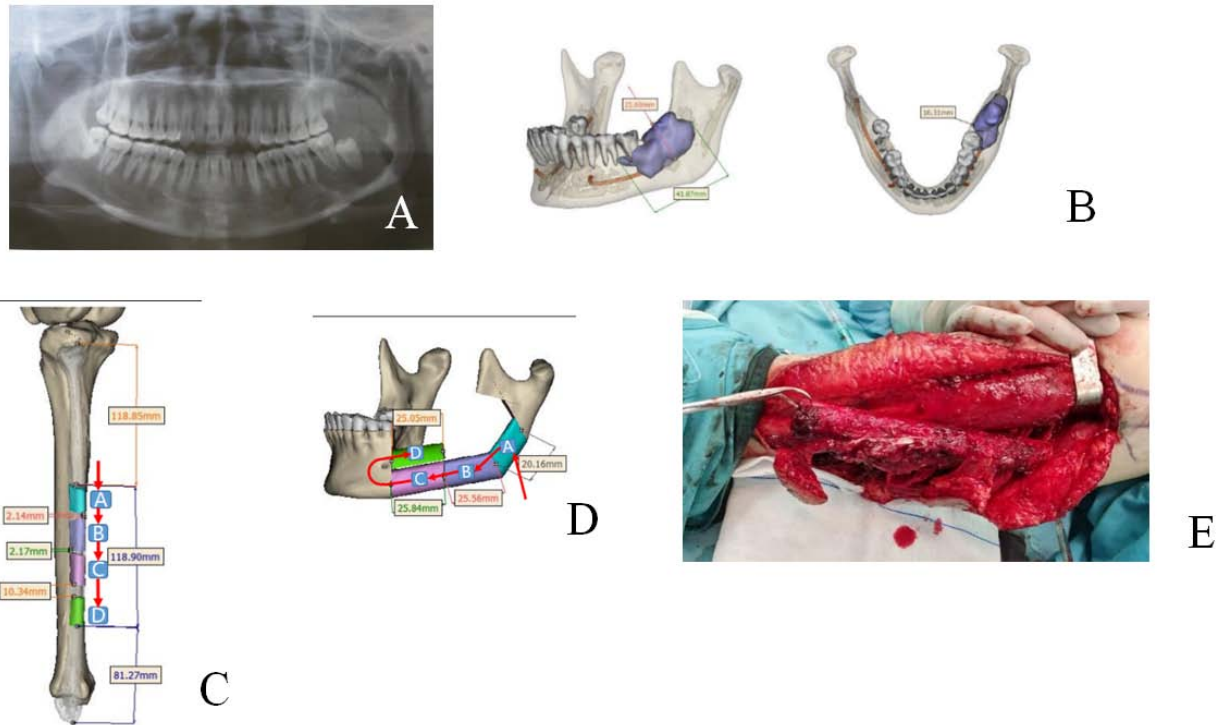


Figure 1. Preoperative and postoperative imaging data and pathological sections of patients without recurrence.

4. Discussion

Simple fenestration decompression may have the problem of a high postoperative recurrence rate and unable to effectively remove the focus. Simple curettage is easy to damage important tissue structures such as inferior alveolar nerve tube, permanent tooth germ and maxillary sinus. Some studies have said that the recurrence rate of simple curettage can be as high as 50-100% [11-13]. In view of the shortcomings of the above operation methods, the research group adopts the sequence method.

First, the fenestration decompression is performed until the change of cystic cavity is not significant or the bone growth is good, Endoscopic curettage can be performed on the premise that the relevant important anatomical structures have been protected. If the patients with recurrence after the operation are not yet adults, they can continue endoscopic curettage, delay the osteotomy time, and preserve the jaw and teeth as much as possible, which will help to improve the quality of life of the patients. Osteotomy can be performed according to the situation when the patient become adults. The use of endoscopy technology in curettage can enter the tumor tissue through the micro-lens, minimize the small residues in the curettage process, reduce the postoperative recurrence rate [14, 15], and help locate and enlarge the surgical field of vision. It can not only effectively protect the relevant important anatomical structures such as tooth roots, permanent tooth germs, neural tubes, etc, but also reduce the formation of local scars [16, 17].

The histological classification of the three patients with recurrence in this study was a follicular type. It was reported in the literature [18, 19]. Some literature [20, 21] reported that the recurrence rate of follicular ameloblastoma is higher than that of other tissue types, mainly because the tumor cells of follicular ameloblastoma proliferate actively and can invade local tissues, while the plexiform type is in the early stage of tumor development, with a low degree of malignancy and low recurrence rate.

In conclusion, sequence therapy can play a good therapeutic effect on young patients with large cystic classic am. The deficiency of this study is that the postoperative follow-up time of individual cases is short, the overall number of cases is small, and the long-term recovery of stage III osteotomy patients has not been observed. In the later stage, the number of cases will be increased, and the patients will continue to be followed up for a long time, so as to clarify the long-term effect of sequence therapy on young patients with large cystic classic AM.

References

- [1] Effiom OA, Ogundana OM, Akinshipo AO, Akintoye SO. Ameloblastoma: current etiopathological concepts and management [J]. *Oral Dis*. 2018, 24(3):307-316.
- [2] Fuchigami T, Ono Y, Kishida S, Nakamura N. Molecular biological findings of ameloblastoma [J]. *Jpn Dent Sci Rev*. 2021, 57(9):27-32.
- [3] Yang Z, Liang Q, Yang L, Zheng GS, Zhang SE, Lao XM, Liang YJ, Liao GQ. Marsupialization of mandibular cystic ameloblastoma: Retrospective study of 7 years [J]. *Head Neck*. 2018, 40(10):2172-2180.
- [4] Mehngi Rajiv, Rajendra Kamala, Bhagwat Pooja, et al. Clinical and Histopathological Analysis of Odontogenic Tumors in Institution-A 10 Years Retrospective Study [J]. *The journal of contemporary dental practice*. 2018, 19(10):1288-1292.
- [5] Hendra FN, Van Cann EM, Helder MN, Ruslin M, de Visscher JG, Forouzanfar T, de Vet HCW. Global incidence and profile of ameloblastoma: A systematic review and meta-analysis [J]. *Oral Dis*. 2020, 26(1):12-21.
- [6] Neagu D, Escuder-de la Torre O, Vázquez-Mahía I, et al. Surgical management of ameloblastoma. Review of literature [J]. *JClin Exp Dent*, 2019, 11(1): e70-e75.
- [7] Haq J, Siddiqui S, McGurk M. Argument for the conservative management of mandibular ameloblastomas [J]. *Br J Oral Maxillofac Surg*. 2016, 54(9):1001-1005.
- [8] Al-RawiNatheer H, Al-Siraj Ammar K, Majeed Ahlam H. Comparison of osteoclastogenesis and local invasiveness of ameloblastoma and keratocystic odontogenic tumor [J]. *European journal of dentistry*. 2018, 12(1):36-42.
- [9] El-Naggar AK, Chan JKC, Grandis JR, et al. WHO classification of head and neck tumors [M]. Lyon: IARC Press, 2017: 217-218.
- [10] Arora S, Kanneppady S K, Banavar S R, et al. Mandibular hemangio-ameloblastoma [J]. *QJM: monthly journal of the Association of Physicians*. 2019, 112(8):615-616.
- [11] Zhang LL, Yang R, Zhang L, Li W, MacDonald-Jankowski D, Poh CF. Dentigerous cyst: a retrospective clinicopathological analysis of 2082 dentigerous cysts in British Columbia, Canada[J]. *Int J Oral Maxillofac Surg*. 2010, 39(9):878-882.
- [12] Bedi RS, Chugh A, Pasricha N. Ameloblastic carcinoma of maxilla [J]. *Natl J Maxillofac Surg*. 2012, 3(1):70-74.
- [13] Ooi A, Feng J, Tan HK, et al. Primary treatment of mandibular ameloblastoma with segmental resection and free fibula reconstruction: achieving satisfactory outcomes with low implantprosthetic rehabilitation [J]. *PlastReconstrAesthet Surg*. 2014, 67(4): 498-505.
- [14] Mak W, Webb D, Al-Salihi S, et al. Sinonasal inverted papilloma recurrence rates and evaluation of current staging systems [J]. *Rhinology*. 2018; 56(4):407-414.
- [15] Embaló Bubacar, Parize Hian Nivaldo, Rivero Elena Riet Correa. Evaluation of cell proliferation in cystic lesions associated with impacted third molars [J]. *Microscopy research and technique*. 2018, 81(11):1241-1245.
- [16] Cakarer Sirmahan, Isler S Cemil, Keskin Basak, et al. Treatment For The Large Aggressive Benign Lesions Of The Jaws [J]. *Journal of maxillofacial and oral surgery*. 2018, 17(3):372-378.
- [17] Shinpei Matsuda, Hitoshi Yoshimura, Hisato Yoshida, et al. Three-Dimensional Volumetric Analysis of Unicystic Ameloblastoma before and after Marsupialization Using OsiriX Software [J]. *Journal of Hard Tissue Biology*. 2019, 28(2):233-236.
- [18] Miguel Gómez-Polo, Rocío, et al. Does Length, Diameter, or Bone Quality Affect Primary and Secondary Stability in Self-Tapping Dental Implants? [J]. *Journal of Oral & Maxillofacial Surgery*, 2016, 74(7):1344-53.